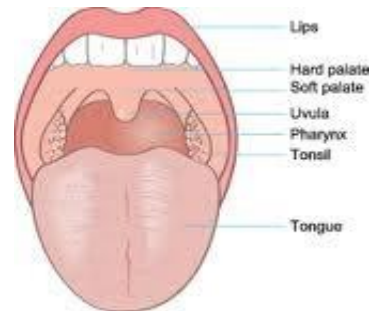


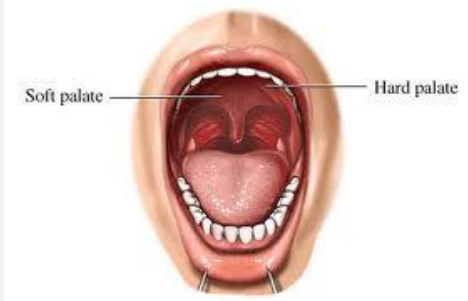





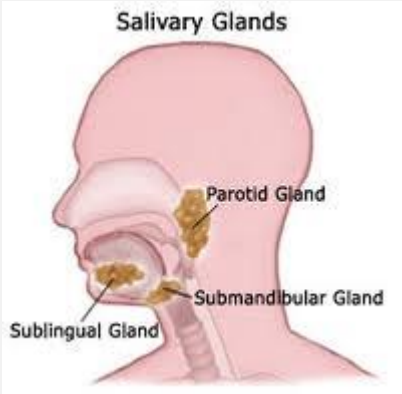
## The Human Mouth

The mouth is the beginning of the digestive tract, otherwise known as the alimentary canal. The mouth has a number of very important functions involved in the digestion of food, breathing, communication and the immune system. The boundaries of the mouth are formed by the lips, cheeks, floor of the mouth, and palate. The mouth contains the teeth and tongue and receives secretions from the salivary glands.



### Anatomy and Physiology of The mouth

Structure	Function	
<b>Lips</b>	The lips form the barrier between the mouth cavity and the outside world. They are also involved in communication, specifically in the formation of words. They contain receptors sensitive to heat and texture.	
<b>Cheeks</b>	The cheeks also aid in the formation of words and hold food in place whilst chewing.	
<b>Palate</b>	The palate consists of two parts, known as the hard palate and the soft palate. The hard palate, which is the anterior part, makes up the roof of the mouth, is supported by bone and provides a rigid surface. The posterior portion, which is the soft palate, is skeletal muscle and connective tissue. The soft palate ends in a projection called the uvula. During swallowing, the soft palate and uvula move upward to direct food away from the nasal cavity and into the oropharynx, which is the area at the back of the mouth.	
<b>Tongue</b>	The tongue is made up of muscle fibres which are attached to the floor of the mouth posteriorly. Main functions of the tongue are to move food around the mouth and to assist in communication and the formation of words. The tongue is also a sense organ that allows us to taste food.	

<p><b>Teeth</b></p>	<p>In a human, there are thirty two teeth in a complete permanent set. The shape of each tooth type corresponds to the way it handles food. At the front are eight chisel shaped cutting teeth, or incisors. Behind these are the four canine teeth for tearing, and behind these are eight premolars and twelve molars for grinding.</p>	
<p><b>Tonsils</b></p>	<p>The tonsils are found at the back of the mouth between the fauces. They are two small glands made of lymphatic tissue. The function of the tonsils is to trap bacteria and viruses which you may breathe in. Antibodies and immune cells in the tonsils help to kill germs and help to prevent throat and lung infections.</p>	
<p><b>Salivary Gland</b></p>	<p>The salivary glands are small glands which produce saliva. They lie underneath the mucous membrane. The largest salivary glands are the parotid glands which lie just in front of the ears, on each side. The submandibular glands, in the floor of the mouth, and the sublingual glands, underneath the tongue, are also large. Saliva is the first part of the digestive process. It moistens the food and also contains the enzyme, amylase, which breaks down starch which would otherwise be indigestible.</p>	

---

## LexiMed Consultants

---

- ❖ **Dr Frank Anning**  
Ear, Nose and Throat Surgeon
- ❖ **Dr Brendan Nasser**  
Dental Surgeon

- ❖ **Dr Andrew Renaut**  
Colorectal and General Surgeon