

The Foot

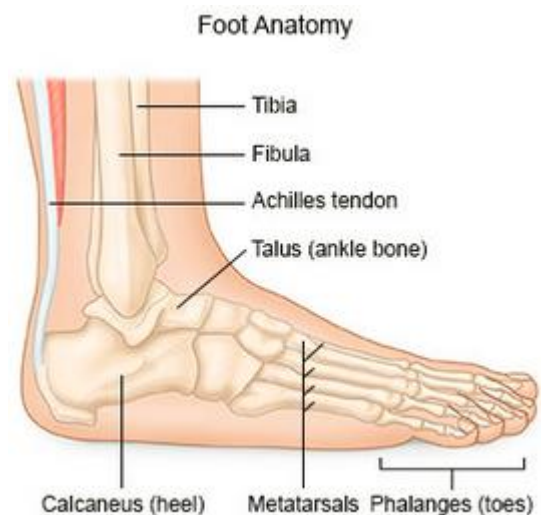
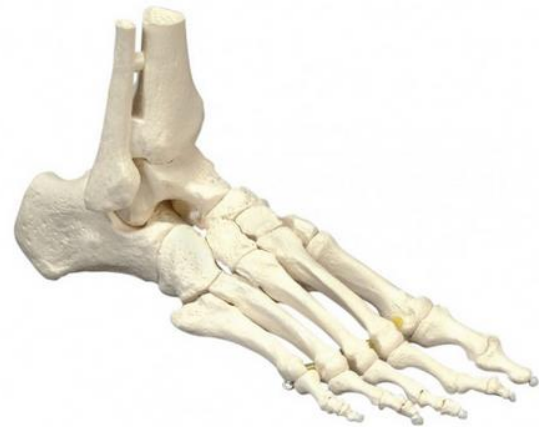Summary

Did you know that a quarter of the bones in the human body are in the feet? Each foot is made up of twenty six bones, thirty joints and more than one hundred muscles, tendons and ligaments, all of which work together to provide support, balance and mobility, allowing us to stand upright and perform activities like walking, running and jumping.

Bones

The twenty six bones in the foot can be broken down as follows:

- ❖ **Talus** – The talus is the bone on top of the foot that forms the ankle joint with the tibia and fibula. The talus transmits the weight of the entire body to the foot.
- ❖ **Calcaneus** – The calcaneus is the largest bone in the human foot and lies beneath the talus to form the heel bone. The calcaneus takes the weight of the body as the heel hits the ground when walking.
- ❖ **Tarsals** – The tarsals are five irregularly shaped bones of the midfoot that form the foot's arch. The tarsal bones are the cuboid and navicular, and the medial, intermediate and lateral cuneiforms.
- ❖ **Metatarsals** – The metatarsals are five bones that make up the forefoot. They connect the phalanges to the tarsals.
- ❖ **Phalanges** – Phalanges are the fourteen bones that make up the toes. The big toe consists of two phalanges, the distal and the proximal, whilst the other toes have three phalanges, the proximal, intermediate and distal.
- ❖ **Sesamoids** – The sesamoids are two small, pea shaped bones that are embedded within a tendon in the ball of the foot beneath the big toe joint.



Subtalar Joint

The subtalar joint, also known as the talocalcaneal joint is formed by two bones in the foot, the talus and the calcaneus. The subtalar joint allows eversion (external rotation) and inversion (internal rotation) of the foot.

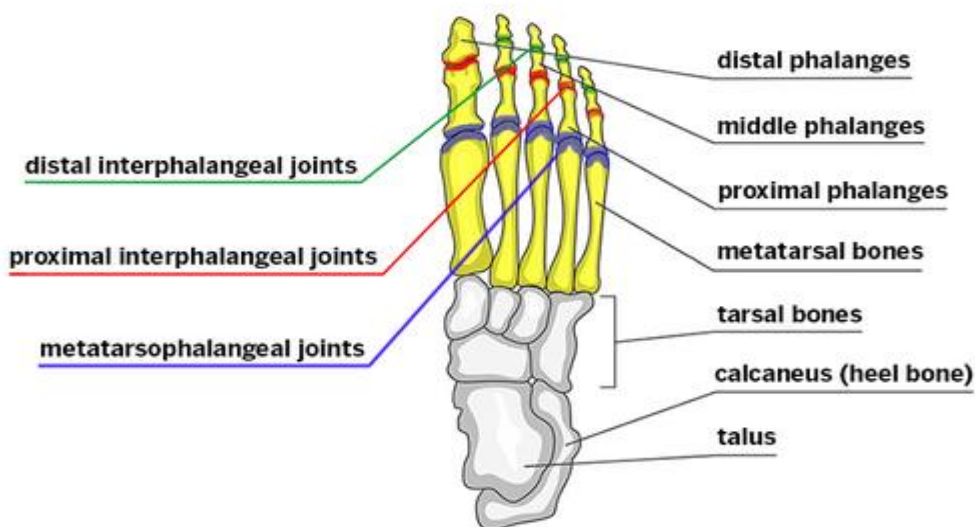
Toe Joints

Apart from the big toe, each of the toes has three joints:

- the **metatarsophalangeal (MTP) joint** (the joint at the base of the toe);
- the **proximal interphalangeal (PIP) joint** (the joint in the middle of the toe); and
- the **distal interphalangeal (DIP) joint** (the joint closest to the tip of the toe).

The big toe differs slightly in that it only has two joints:

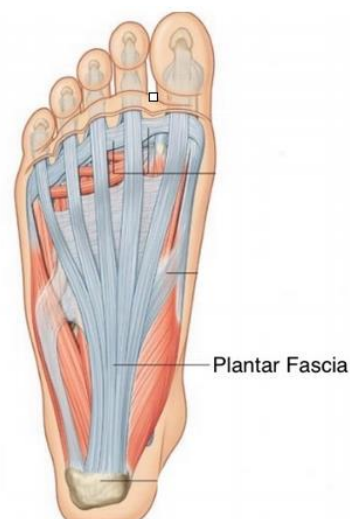- the **metatarsophalangeal (MTP) joint** (the joint at the base of the big toe); and
- the **interphalangeal (IP) joint** (the joint closest to the tip of the big toe).



Ligaments

Ligaments are tough, flexible, fibrous tissues that act like strong ropes to connect bones to other bones, preventing too much motion and promoting stability. The main ligaments in the foot are:

- the **plantar fascia** which is the longest ligament of the foot and connects the heel bone to the toes. By stretching and contracting, the plantar fascia helps us balance and gives the foot strength for walking;
- the **plantar calcaneonavicular ligament** which supports the head of the talus; and
- the **calcaneocuboid ligament** which supports the arch of the foot.



Tendons

The foot has many tendons that attach bones and ligaments together to maintain the foot's arch. The main tendon is the Achilles tendon. You can feel your Achilles tendon at the back of your heel. This tendon assists with plantar flexion of the foot, making it possible for us to run, jump, climb stairs and stand on our toes.

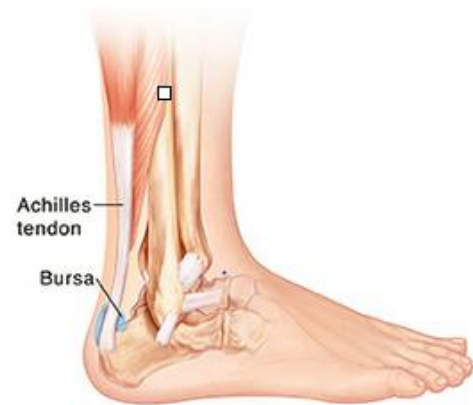Muscles

There are twenty muscles that give the foot its shape, support and ability to move. The main muscles in the foot are:

- the **tibialis posterior** muscle which supports the foot's arch;
- the **tibialis anterior** muscle which allows the foot to move upward;
- the **tibialis posterior** muscle which controls movement on the outside of the ankle;
- the **extensors** which help the ankle raise the toes to initiate the act of stepping forward; and
- the **flexors** which help stabilise the toes against the ground.

Bursa

A bursa is a small fluid filled sac that cushions and lubricates the foot. There is only one bursa in the foot, the retrocalcaneal bursa, which is located in the back of the foot between the heel bone and the Achilles tendon.



LexiMed Consultants

- **Dr Peter Winstanley**
Orthopaedic Surgeon
- **Dr David Shooter**
Orthopaedic Surgeon
- **Dr Ross Kennedy**
Orthopaedic Surgeon
- **Dr Richard Hudson**
Orthopaedic Surgeon

- **Dr David Ness**
Orthopaedic Surgeon
- **Dr Warren Todd**
Orthopaedic Surgeon
- **Dr Gregory Bookless**
Orthopaedic Surgeon
- **Dr Glenn Davies**
Orthopaedic Surgeon

- **Dr Kingsley Foote**
Orthopaedic Surgeon
- **Dr Michael South**
Orthopaedic Surgeon
- **Dr Price Gallie**
Orthopaedic Surgeon
- **Dr Burce Love**
Orthopaedic Surgeon

References:

- <https://www.arthritis.org/about-arthritis/where-it-hurts/foot-heel-and-toe-pain/foot-anatomy.php>
- <https://teachmeanatomy.info/lower-limb/bones/bones-of-the-foot-tarsals-metatarsals-and-phalanges/>
- <https://www.healthdirect.gov.au/plantar-fasciitis>
- <https://www.anatomynext.com/subtalar-joint/>
- <https://teachmeanatomy.info/lower-limb/joints/subtalar/>
- <https://www.webmd.com/pain-management/picture-of-the-feet#1>
- <https://www.medicalnewstoday.com/articles/324336.php#conditions-affecting-the-foot-bones>
- <https://www.healthline.com/human-body-maps/foot#1>
- <http://www.healthcommunities.com/foot-anatomy/muscles-tendons-ligaments.shtml>