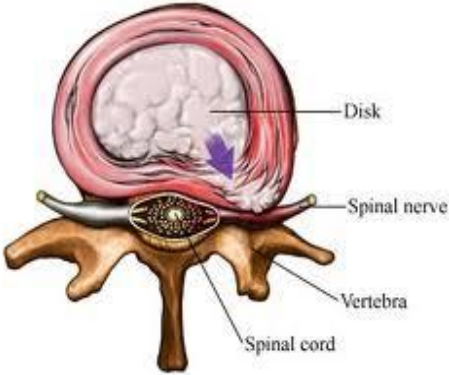



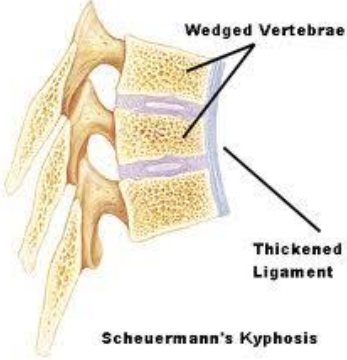
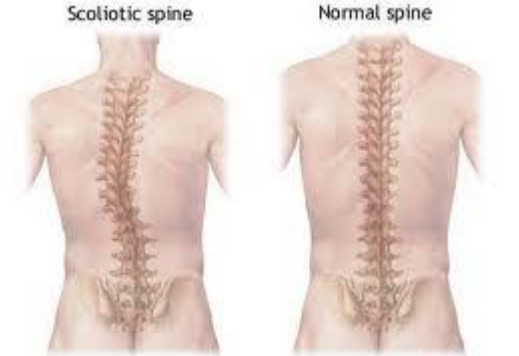

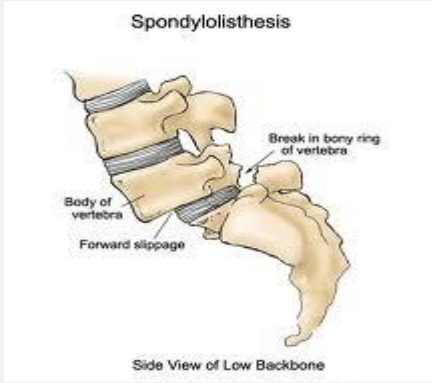



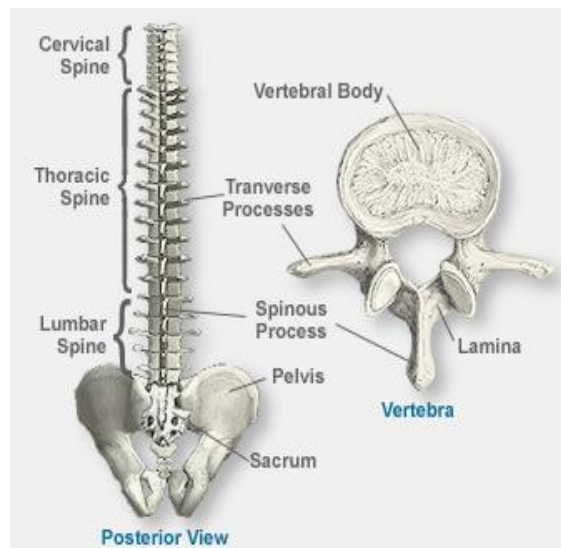
Spinal Conditions

Medical Conditions of the Spine

Condition	Description	Image
Annular Tear	<p>An annular tear describes a hole or rip in the outer vertebral disc wall, called the annulus fibrosus. This wall is made up of many inter woven layers of cells and is very strong and durable. However, due to disc injury or spinal degeneration, the outer wall can become compromised, creating a bulging disc, or torn, creating a ruptured disc.</p>	
Desiccation	<p>Desiccation means, in broad terms, the removal of water. In relation to the spine, disc desiccation can occur with age, meaning the inter vertebral discs become less spongy, absorb less shock, therefore causing increased friction, giving rise to back pain.</p>	
Kyphosis	<p>Kyphosis is an outward curvature of the upper back. It can be either the result of degenerative diseases such as arthritis, developmental problems with the most common example being Scheuermann's disease, osteoporosis with compression fractures of the vertebrae, and/or trauma.</p>	

<p>Sciatica</p>	<p>Sciatica is a symptom of a problem with the sciatic nerve, a large nerve that runs from the lower back down the back of each leg. Sciatica causes pain, weakness, numbness or tingling. It can start in the lower back and extend down the leg to the calf, foot, or even the toes. Sciatica may be due to a ruptured intervertebral disc, narrowing of the spinal canal that puts pressure on the nerve called spinal stenosis, or an injury such as a pelvic fracture. In many cases no cause can be found.</p>	
<p>Scheuermann's disease</p>	<p>Scheuermann's disease is a relatively common condition arising from abnormal development of the spine during puberty. It is also known as Sherman's Disease, Scheuermann's kyphosis (since it results in kyphosis), Calvé disease and Juvenile Osteochondrosis of the Spine. It is named after Holger Werfel Scheuermann.</p>	
<p>Scoliosis</p>	<p>Scoliosis is when a person's spine is curved from side to side. On an x-ray, viewed from the rear, the spine of an individual with scoliosis may look more like an "S" or a "C" rather than a straight line.</p>	
<p>Spondylosis</p>	<p>Spondylosis is a common degenerative condition of the cervical spine. It is most likely caused by age related changes in the intervertebral disks. It may cause pressure on nerve roots with subsequent sensory and, or motor disturbances, causing pain or numbness.</p>	

<p>Spondylolisthesis</p>	<p>When spondylosis occurs it can give rise to spondylolisthesis, the partial forward dislocation of one vertebra over the one below it, most commonly the fifth lumbar vertebra over the first sacral vertebra. Severity of spondylolisthesis is classified by percentage of slip.</p>	 <p style="text-align: center;">Spondylolisthesis</p> <p style="text-align: center;">Side View of Low Backbone</p>
<p>Stenosis</p>	<p>Spinal stenosis causes narrowing in the spine. The narrowing can occur at the centre of the spine, in the canals branching off the spine and, or between the vertebrae. The narrowing puts pressure on the nerves and spinal cord and can cause pain.</p>	 <p style="text-align: right;">Spinal stenosis from disc herniation</p>



LexiMed Consultants

- ❖ **Dr David Shooter**
Orthopaedic Surgeon
- ❖ **Dr David Ness**
Orthopaedic Surgeon
- ❖ **Dr Greg Bookless**
Orthopaedic Surgeon
- ❖ **Dr Leigh Atkinson**
Neurosurgeon
- ❖ **Dr Peter Winstanley**
Orthopaedic Surgeon
- ❖ **Dr Kingsley Foote**
Orthopaedic Surgeon
- ❖ **Dr Bruce Love**
Orthopaedic Surgeon
- ❖ **Dr Glenn Davies**
Orthopaedic Surgeon
- ❖ **Dr Richard Hudson**
Orthopaedic Surgeon
- ❖ **Dr Steven Hatcher**
Orthopaedic Surgeon