

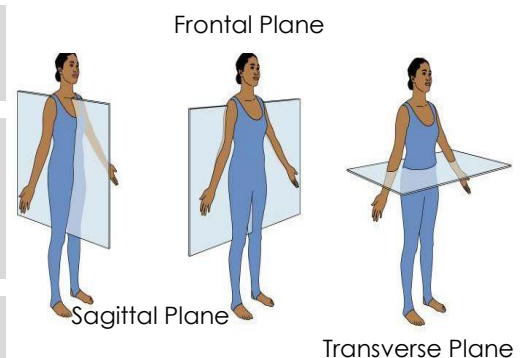
Body Planes and Directional Terms

As part of an Independent Medical Assessment, a specialist may be required to carry out a physical examination of the claimant. When the specialist dictates the report, they will need to refer to the body and the location of its parts in precise detail. In doing this they will use terminology of body planes. They will also use directional terms when communicating the position or location of a condition or injury. Directional terms are also used to describe how a process, organ or body system relates to another.

These are terms that will appear in the finished medicolegal report and on occasion, it can be difficult for the client or claimant to interpret. The tables below should assist in understanding some of these terms.

The Planes

Sagittal Plane	This plane divides the body or any of its parts lengthwise into left and right sides.
Frontal (or Coronal) Plane	This plane divides the body into front (anterior or ventral) and back (posterior or dorsal) portions. This plane slices from right to left.
Transverse or Horizontal Plane	This plane divides the body into the superior (upper) and inferior (lower) parts.



Superior	Above or towards the head	Proximal	Near to or close to
Inferior	Below or towards the feet	Distal	Away from or distant
Anterior	Towards the front of the body	Supine	Lying horizontally, facing down
Posterior	Towards the back of the body	Prone	Lying horizontally, facing up
Ventral	Pertaining to the front	Extension	Making the angle of the joint larger
Dorsal	Pertaining to the back	Flexion	Making the angle of the joint smaller
Medial	Middle of the body	Eversion	Turning outward or inside out
Lateral	Towards the side	Inversion	Turning inward, or reversal of normal
Abduction	To move away from the midline	External	Towards or near the outside
Adduction	To move towards the midline	Internal	Towards or near the inside