

Orthopaedic Disorders

Interesting facts

Orthopaedic is a word derived from the Greek "Ortho" and "Pais" or "straight child". This is because it was originally used as a word to describe children with spine and limb deformities.

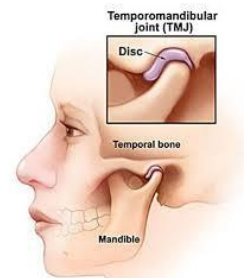
Nowadays, Orthopaedics is more commonly used to describe the study and medical treatment of the musculoskeletal system, namely the bones and muscles. With the complexity of the human musculoskeletal system, this involves the treatment of a wide range of conditions.

Common examples of orthopaedic conditions include trauma, degenerative diseases, infections, tumours, and congenital conditions. These are broad terms covering many more specific conditions.

Common Orthopaedic Conditions

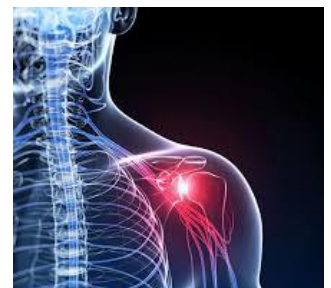Temporomandibular joint (TMJ) syndrome

The temporomandibular joint (TMJ) is the joint connecting your jawbone to the rest of your skull. TMJ syndrome refers to jaw pain in this area, with the root cause sometimes being behavioural for example, through clenching your jaw or grinding your teeth, genetic or a result of an underlying disorder like arthritis.



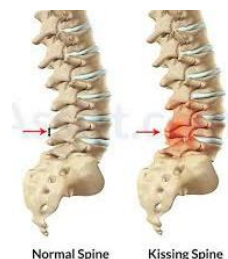Adhesive capsulitis

Adhesive capsulitis, better known as "frozen shoulder", occurs when the tissue in the shoulder, around the humerus, clavicle and bicep becomes stiff. It is treated typically through range of motion therapy and corticosteroid injections.



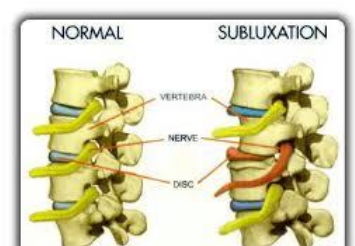
Baastrup's disease

Baastrup's disease, also known as "kissing spine", is a syndrome where the spine has degenerated to the point that two or more adjacent spinous processes touch together. It typically occurs with the L4 and L5 vertebrae, however it can affect other areas as well. It is usually seen in elderly patients.



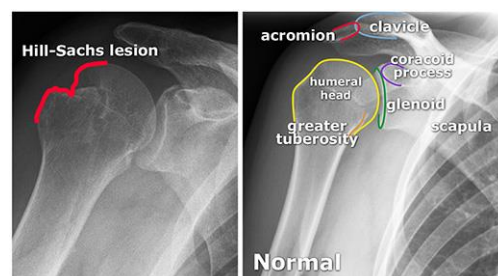
Subluxed

Subluxation refers to when a joint or organ is partially moved out of place. Commonly, subluxation occurs in the spine when the vertebrae are out of alignment. Subluxed is the verb form of subluxation.



A Hill-Sachs deformity

A Hill-Sachs deformity manifests when there is a compression fracture to the top of the humerus. It occurs as a result of a shoulder dislocation when the humerus is forced into the glenoid, and the top of it is chipped off.

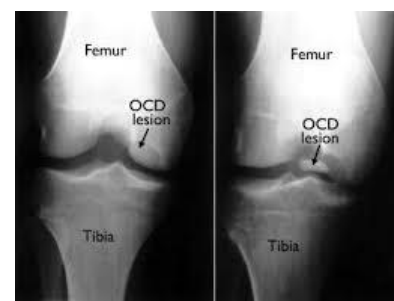


A conjoint tendon

A conjoint tendon is a tendon that connects the ends of two muscles. There is a conjoint tendon in the shoulder joint between the coracobrachialis and the short head of the biceps which is thought to help the shoulder rotate.

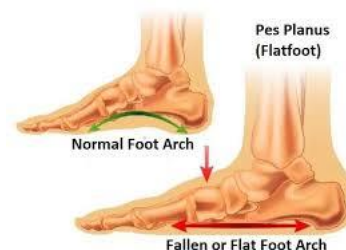Osteochondritis Dissecans

Osteochondritis dissecans is a joint condition in which bone underneath the cartilage of a joint dies due to lack of blood flow. This bone and cartilage can then break loose, causing pain and possibly hindering joint motion. It is most common in children and teens who are active with sport. It most often occurs in the knee, but can also occur in other joints.



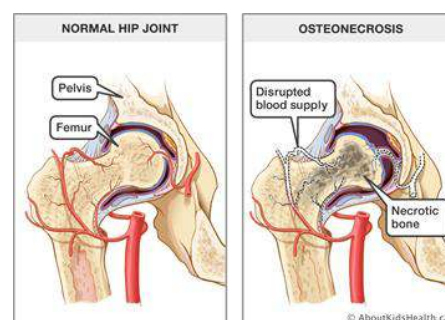
Pes Planus

Commonly known as "flat foot", a condition in which the longitudinal arch in the foot, which runs lengthwise along the sole of the foot, has not developed normally and is lowered or flattened out. One foot or both feet may be affected.



Osteonecrosis | Avascular Necrosis

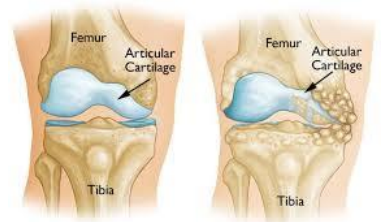
Osteonecrosis, also known as Avascular Necrosis, is associated with alcohol abuse and steroid use and most commonly occurs in the hip. It is a bone disease which is caused by reduced blood flow to the bone. This reduced blood flow causes the bone tissue to die and may cause joints surrounding the bone to collapse. Osteonecrosis can manifest in any bone, however, the most common sites include the thigh bone, upper arm bone, knees, shoulders and ankles. Anyone can develop osteonecrosis however it is most common in people in their 30s, 40s and 50s. Treatment options may be nonsurgical, surgical or both.



Common Orthopaedic Treatments

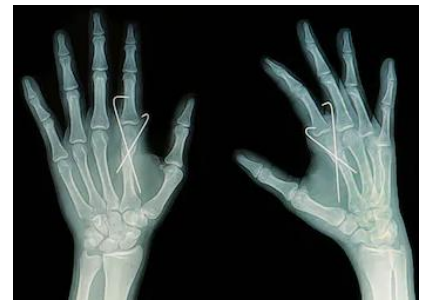
Osteotomy

An osteotomy is a surgery involving cutting or reshaping a bone. It is commonly performed on patients who require realignment of their knee joints, high tibial osteotomy, due to their osteoarthritis wearing away the bone surface.



Kirschner Wire

Kirschner wires, also known as K-wires, were introduced in 1909 by Martin Kirschner. Kirschner wires are sterilised, sharpened, smooth stainless steel pins commonly used in orthopaedics and other types of medical and veterinary surgery. Kirschner wires vary in size and are utilised most frequently to hold certain bone fractures together or to provide an anchor for skeletal traction. Skeletal traction is used for serious fractures, often to realign and stabilise the break, and describes the process whereby pins are inserted into a bone and then weight is applied directly to the bone site to realign.



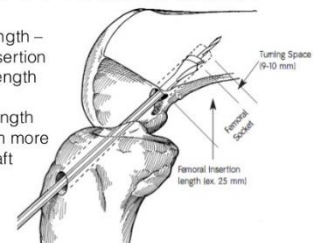
Endobutton

The EndoButton is a commonly used device for femoral fixation of anterior cruciate ligament grafts. The EndoButton is an extra-articular device made of a metallic button and a polyurethane ribbon, Endotape. The button is supported by the external cortical portion of the bone. Endotape links the graft to the not supported central part of the metallic button.

Maths of Endobutton

Femoral tunnel length –
Desired graft insertion
length = Loop length

Insertion tunnel length
should be 10mm more
than desired graft
insertion length



LexiMed Orthopaedic Surgeons

- ❖ Dr Peter Winstanley
- ❖ Dr David Ness
- ❖ Dr Kingsley Foote
- ❖ Dr David Shooter

- ❖ Dr Michael South
- ❖ Dr Ross Kennedy
- ❖ Dr Glenn Davies
- ❖ Dr Richard Hudson

- ❖ Dr Gregory Bookless
- ❖ Dr Price Gallie
- ❖ Dr Bruce Love