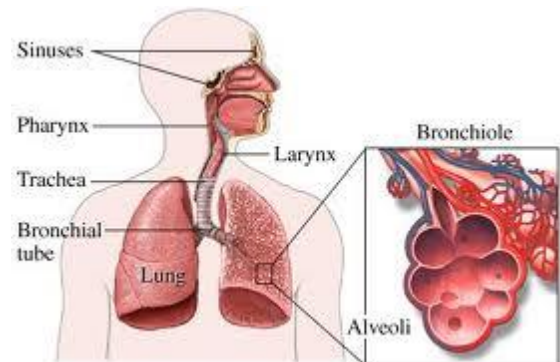


The Respiratory System

We need oxygen to keep our bodies functioning on a cellular level, and the respiratory system is the part of the body that enables this to happen. The respiratory system is a group of organs and tissues that enable us to breathe. The main parts of this system are the lungs, the airways, and the muscles that enable breathing.

Anatomically the respiratory system is divided into three parts, the upper respiratory tract, the airways and the lungs.



The Upper Respiratory Tract

The major passages and structures of the upper respiratory tract include the nose and the nasal cavity, the mouth, the pharynx, and the voice box or larynx.

The respiratory system is lined with a mucous membrane that secretes mucous. The mucous traps smaller particles like pollen or smoke. Hair like structures called cilia line the mucous membrane and move the particles trapped in the mucous out of the nose.

Nose and Nasal Cavity	The nostrils, also known as anterior nares, are the first point of entry of air into the body. Inside the nasal cavity air is warmed, moistened, cleaned and regulated before reaching more delicate and susceptible areas of the respiratory tract.
Mouth	Like the nose, the mouth is an orifice through which an individual can breathe, however, a healthy individual normally breathes through the nose while resting or doing light exercise as the nose is a much more efficient filtering system than the mouth.
Pharynx	The pharynx is a fibromuscular tube and it is divided into the nasopharynx, the oropharynx and the laryngopharynx. It has functions in both the digestive and respiratory tracts. For the respiratory tract, it conducts air from the nasal cavity into the larynx.
Voice Box or Larynx	The larynx is located at the base of the tongue, anterior to the oesophagus. It functions in communication, as well as in the digestive system and the respiratory system. It provides a carefully guarded passageway between the pharynx and the trachea. Stimulation of the larynx produces a strong cough mechanism to stop food matter from entering the lungs.

The Respiratory Airways

The airways are pipes that carry oxygen rich air to the lungs and carbon dioxide, a waste gas, out of the lungs.

The Trachea	Once the air has travelled through the larynx it enters the trachea. As with the upper respiratory tract, the trachea is lined with special cells to help trap dirt and further clean the air before it reaches the lungs.
The Bronchi	The trachea divides into bronchial tubes, left and right, supplying each lung. Each bronchial tube branches out into a primary bronchus which extends into secondary bronchi, getting gradually smaller until they become tiny bronchioles, forming a tree like structure of passageways within the lung.

The Lungs

The lungs are the site of gaseous exchange in the respiratory system.

Respiratory Bronchioles	The respiratory bronchioles are the very smallest branches of the bronchi, and they branch into alveolar ducts.
Alveolar Ducts	The alveolar ducts are the tiny tubes between the bronchioles and the alveolar sacs, and like the alveoli, provide a surface for gaseous exchange.
Alveoli	These are the dead ends of the respiratory tree, and look like tiny little sacs. The alveoli are the gas exchange surface where oxygen flows from the lungs into the blood and carbon dioxide flows from the blood into the lungs to be expired. Each of these air sacs is covered in a mesh of tiny blood vessels called capillaries. The capillaries connect to a network of arteries and veins that move blood through the body.

The Muscles of Respiration

The muscles of respiration aid in both inspiration and expiration, which require changes in the pressure within the chest cavity. The respiratory muscles work to achieve this by changing the dimensions of the chest cavity.

The Diaphragm	During quiet breathing, respiration is mainly controlled by the diaphragm. As it contracts, pressure in the chest cavity lowers, and draws air in down the pressure gradient from the nose or mouth to the alveoli. Breathing out whilst resting is passive, as the respiratory muscles are relaxed and the elastic lung and chest wall return passively to their resting volume.
The Intercostal Muscles	The intercostal muscles are found between the ribs. There are external intercostal muscles which are involved with forced inhalation and internal intercostal muscles which are involved in forced expiration.

LexiMed Consultants

✦ **Dr James McKeon**
Respiratory Physician

✦ **Dr Malcolm Wright**
General and Intensive
Care physician

✦ **Dr Matthew Rickard**
Physician