

The Shoulder

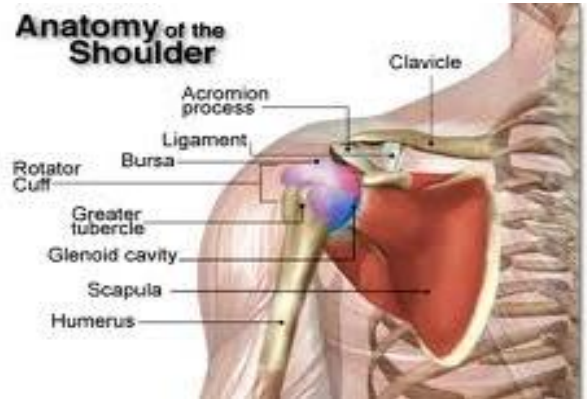
Anatomy of the Shoulder

The shoulder is made up of three bones, the scapula or the shoulder blade, the clavicle or the collar bone and the humerus or the bone in the upper arm. These bones are joined with two joints. These joints are the acromioclavicular (AC) joint and the glenohumeral joint which is the traditional ball and socket joint that allows complete range of motion in the shoulder.

These bones and joints are held together by muscles, tendons, and ligaments. Tendons, which are tough cords of tissue that attach the shoulder muscles to bone, and ligaments which attach bones to bones, provide additional strength and stability.

The rotator cuff tendons hold the ball in the socket of the glenohumeral joint and provide mobility and strength to the shoulder joint. There are two bursa that cushion and protect the rotator cuff from the bony arch of the shoulder blade to allow smooth movement of the joint.

Being the most movable joint in the body makes the shoulder fairly unstable and more prone to injury.

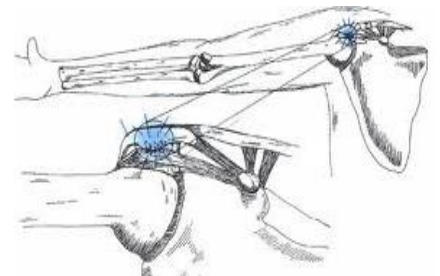


Shoulder Conditions

Rotator Cuff Tendonitis

Rotator cuff tendonitis is an inflammation, or irritation and swelling, of the tendons of the shoulder caused by repeated abduction and forward flexion of the upper arm, and these movements begin to cause pain.

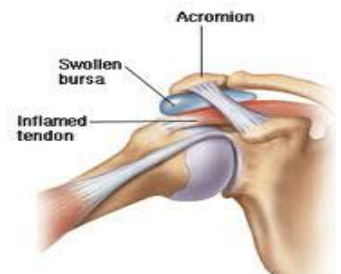Rotator cuff tendonitis is also related to degenerative and age related changes in the rotator cuff tendon.



Bursitis

The bursa is a fibrous sac which creates a cushion between certain tendons and the bones beneath them.

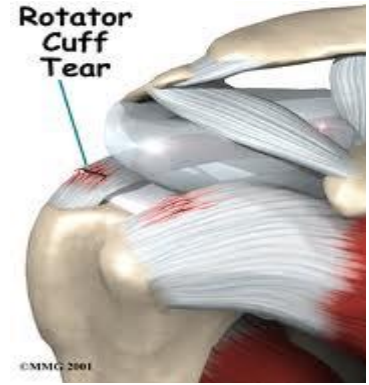Inflammation of the bursa is known as bursitis. Bursitis may be precipitated by arthritis, infection, injury, or trauma.



Rotator Cuff Tear

A rotator cuff tear often occurs following rotator cuff tendonitis, particularly if there is degeneration present. A relatively minor work injury can result in a torn rotator cuff in this instance. The tear can be full or partial.

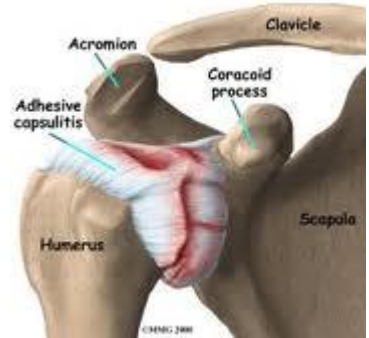Surgical intervention and recovery largely depends on the quality of the tendon.



Frozen Shoulder

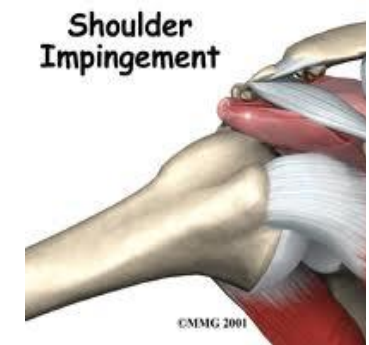
The frozen shoulder is characterised by severe pain and stiffness with loss of global movement. There is some argument as to whether the cause is related to constitutional factors, or trauma.

The glenohumeral joint becomes inflamed and stiff.



Impingement Syndrome

Pain usually occurs when the arm is flexed and abducted, especially if the arm is rotated. In this position the rotator cuff is most compressed as it passes under the anterior edge of the acromion. The patient has difficulty working with the arm above the level of the shoulder.



LexiMed Consultants

- ❖ **Dr David Shooter**
Orthopaedic Surgeon
- ❖ **Dr Glenn Davies**
Orthopaedic Surgeon

- ❖ **Dr Steven Hatcher**
Orthopaedic Surgeon

- ❖ **Dr Richard Hudson**
Orthopaedic Surgeon